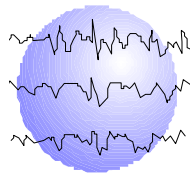


# MAGNETIC SOURCE IMAGING VS. THE WADA TEST IN LANGUAGE LATERALIZATION

Robert C. Doss, PsyD  
Wenbo Zhang, MD, PhD  
Gail L. Risse, PhD  
Deanna L. Dickens, MD



This paper has been prepared specifically for:

American Epilepsy Society Annual Meeting  
San Diego, CA  
December 1 - 5, 2006

Please consider this information to be preliminary findings.

Abstract published: *Epilepsia* 47(S4);95[1.190]2006

Minnesota Epilepsy Group, P.A.<sup>®</sup>  
225 Smith Avenue N., Suite 201  
St. Paul, MN 55102  
Phone: (651) 241-5290  
Fax: (651) 241-5248

## **Introduction:**

Magnetoencephalography (MEG)/Magnetic Source Imaging (MSI) is a completely non-invasive technique, which has been used to localize epileptic foci, somatosensory, and motor functions in the brain. More recently, MSI has been also used to lateralize and localize language specific regions in the brain. This information can be invaluable in planning the approach and extent of surgical resection in order to avoid eloquent cortical speech areas.

To date, the Wada test or Intracarotid Amobarbital Procedure (IAP) has been the gold standard in determining speech/language lateralization for presurgical planning. The potential for MSI to replace the invasive IAP for language lateralization is very high. Papanicolaou et al. (2004) recently examined the relationship between MSI and IAP language lateralization in 85 cases and found a 93% concordance rate for determining language in the hemisphere to be treated. Clinically-based language mapping with MSI has been reported in very few institutions.

The purpose of this research is to validate lateralized MSI language mapping in patients who have also undergone IAP using the Minnesota Epilepsy Group protocol.

## **Methods:**

Thirty subjects (age 15-57 years) with epilepsy and/or brain tumor were identified from the Minnesota Epilepsy Group clinic records. Please see Table 1 for group characteristics.

All subjects had previously undergone an IAP but not resective brain surgery. The IAP was conducted using a protocol developed at the Minnesota Epilepsy Group. All IAPs were completed when the subjects were 12 years or older. Language lateralization was determined by the patient's ability to produce and/or understand meaningful speech at maximal drug effect (i.e., zero motor response). Language scores were quantified based upon automatic speech, naming, reading, and comprehension responses. An IAP asymmetry index was calculated using the formula  $(R-L)/(R+L)$  where R and L refer to the language scores obtained by the right and left hemisphere, respectively. Thus, left hemisphere language dominance was defined by a score of  $-1$ , while right dominance was defined by a score of  $+1$ . All patients with scores between these two values were classified as bilateral. Calculation of IAP asymmetry indexes for four subjects was not possible secondary to incomplete data.

For the MSI language mapping, an auditory stimuli system (Apple Macintosh, SuperLab software, and sound amplification) was used to deliver a pre-designed task (word recognition) that has been developed and reported previously (Papanicolaou et al., 2004). The MEG unit consisted of a 148-channel Magnes 2500 WH system (4-D Neuroimaging, San Diego, CA). The author who completed the MSI language analysis (W.Z.) was blinded to the patients' IAP test results. Single equivalent current dipole (ECD) model was used in the analysis of language data and has been validated by other institutions. Selection of dipoles was restricted to the lateral temporal lobe including the perisylvian region of both cerebral hemispheres. Mesial temporal activations were not included in these analyses.

Laterality judgments for the MSI data were based on the formula:  $(R-L)/(R+L)$ . Index values between -0.1 and 0.1 were considered to denote bilateral language activation. Values greater than 0.1 or less than -0.1 were indicative of right or left hemisphere dominance, respectively.

## Results

The IAP and MSI were consistent in identifying the primary language hemisphere in 81% of the cases, based on the asymmetry indexes alone ( $n = 26$ ). This is graphically represented by the scatter plot in Figure 2.

Table 2 shows the concordance between the IAP and MSI in determining whether language resides in the hemisphere to be treated when using clinical laterality judgments. The correct classification rate was 87% with sensitivity and specificity values of 100% and 67%, respectively,  $\chi^2(4, N = 30) = 16.43, p < .001$ .

Three of the four discordant cases were identified as having bilateral language by either method based on clinical laterality judgments. One case showed left language dominance by IAP and right dominance by MSI.

A second analysis was undertaken with only left language dominant IAP cases. Table 3 shows the concordance between the IAP and MSI at 95% with sensitivity and specificity values of 100% and 83%, respectively,  $\chi^2(4, N = 30) = 15.6, p < .001$ .

## Conclusions:

- The IAP and MSI were consistent in identifying the primary language hemisphere in 81% of the cases, based on the asymmetry indexes.
- The concordance between the IAP and MSI to detect language in the hemisphere being considered for intracranial hardware and/or surgery was 87%, with the MSI showing four false negatives.
- When the above analysis is restricted to only left dominant IAP cases, the correct classification rate improved to 95%. This study included 10 (33%) atypical (bilateral or right dominant) IAP language cases, which underscores the uniqueness of this sample. At our institution, the overall incidence of atypical language lateralization determined by IAP is 17% based on 569 procedures. We believe that these sample characteristics may explain some of the discrepant findings in this study.
- These results suggest that MSI may be a viable replacement for the IAP in the presurgical determination of language lateralization.
- MSI language data needs to be considered in the context of other pre-surgical clinical information especially when bilateral language representation is suggested.

## References:

1. Papinicolaou, A.C., et al (2004). Magnetoencephalography: a noninvasive alternative to the Wada Procedure. Journal of Neurosurgery, 100, 867-876.

Table 1

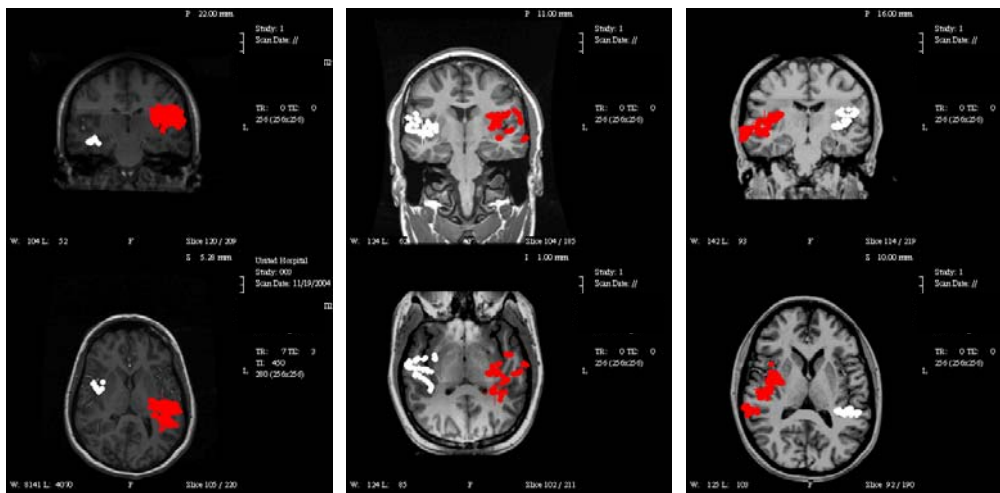
## Patient Characteristics

N	30
Age at IAP <sup>1</sup>	26.8 (13.0)
Age at MSI <sup>1</sup>	27.6 (12.4)
Gender (% Male)	53%
Handedness (% Right)	73%
Education <sup>1</sup>	12.5 (2.3)
Full Scale IQ <sup>1</sup> (FSIQ)	91.4 (14.2)
Age of Seizure Onset <sup>1</sup>	14.3 (13.3)
Laterality of Pathology	
Left	22
Right	7
Bilateral	1
Etiology	
Seizure	21
Tumor	1
Tumor/Seizure	8

<sup>1</sup> = *M(SD)*

Figure 1

## Typical Activation Profiles



Left Dominant

Bilateral

Right Dominant

Note: These figures represent composite MEG receptive language activation sites merged onto a central slice from 3T MRI

Figure 2

Scatter Plot of Asymmetry Indexes

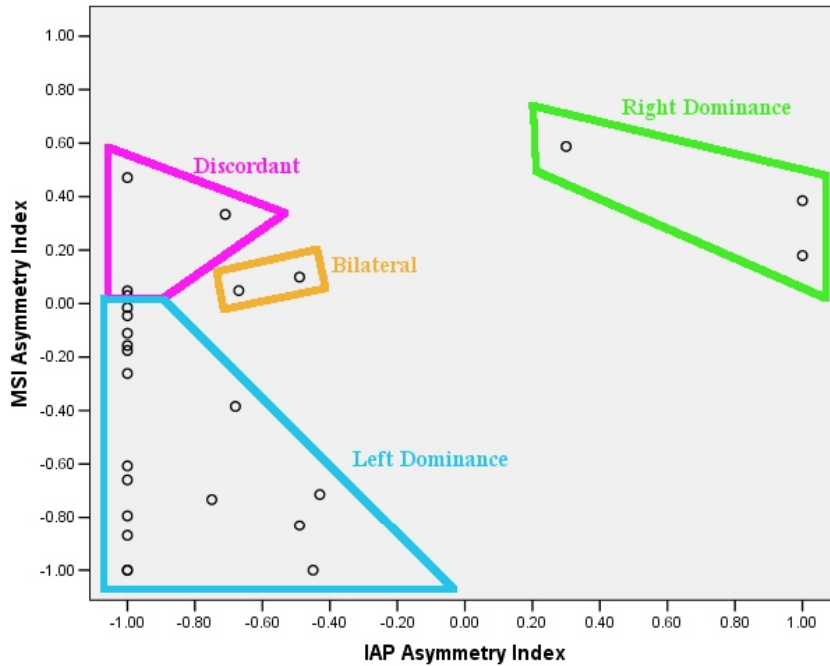


Table 2

Concordance of IAP & MSI Clinical Judgments of Language in the Hemisphere to be Treated

		MSI	
		Lang. Present	Lang. Absent
IAP	Lang. Present	18	4
	Lang. Absent	0	8

Sensitivity = 100%  
 Specificity = 67%  
 Overall Correct Classification = 87%  
 $\chi^2 (4, N = 30) = 16.4, p < .001$

Table 3

Concordance of IAP & MSI Clinical Judgments of Language in the Hemisphere to be Treated For IAP **Left Dominant-Only** Cases

		MSI	
		Lang. Present	Lang. Absent
IAP	Lang. Present	14	1
	Lang. Absent	0	5

Sensitivity = 100%  
 Specificity = 83%  
 Overall Correct Classification = 95%  
 $\chi^2 (4, N = 20) = 15.6, p < .001$