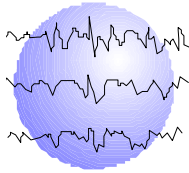


LOCALIZATION OF RIGHT HEMISPHERE LANGUAGE ACTIVATION IN MAGNETIC SOURCE IMAGING: CORRELATION WITH RIGHT HEMISPHERE LANGUAGE RESPONSES ON IAP

Gail L. Risse, PhD
Robert C. Doss, PsyD
Wenbo Zhang, MD, PhD
John R. Gates, MD



This paper has been prepared specifically for:

American Epilepsy Society Annual Meeting
Washington, DC
December 2 - 6, 2005

Please consider this information to be preliminary findings.

Abstract published: *Epilepsia* 46(8);70[1.164]2005

Minnesota Epilepsy Group, P.A.[®]
225 Smith Avenue N., Suite 201
St. Paul, MN 55102
Phone: (651) 241-5290
Fax: (651) 241-5248

REVISED ABSTRACT

RATIONALE: Recent studies have reported a high rate of concordance between magnetoencephalography/magnetic source imaging (MSI) and the Intracarotid Amobarbital Procedure (IAP) in identifying patients with left hemisphere language dominance, despite the frequent co-occurrence of some right hemisphere activation on MSI. This study examines the anatomical activation patterns in the right hemisphere in response to an auditory word recognition task in patients who were classified with bilateral language based on the IAP.

METHODS: Data from ten patients diagnosed with chronic epilepsy and/or brain tumor who had undergone the IAP and language mapping with MSI were retrospectively reviewed. Based on the results of the IAP, six patients were classified as having bilateral language, while the remaining four demonstrated exclusive left hemisphere language dominance. MSI data were obtained with a 148-channel Magnes 2500 WH system (4-D Neuroimaging, San Diego, CA) and analyzed using the single equivalent dipole model. For each patient, the anatomic location of right hemisphere activation sites on MSI was examined in relation to modality-specific IAP language responses scored for the right hemisphere.

RESULTS: Five of 6 bilateral language patients demonstrated some receptive language function in the right hemisphere on IAP and 4 of 6 had one or more correct responses on tasks of automatic speech and/or naming during maximum drug effect following the left injection. Right hemisphere MSI language activation sites included the superior temporal gyrus and/or temporal parietal junction in 5 of 6 patients. The fifth patient showed activation in the right inferior frontal region and a portion of the insula. This patient had the highest right hemisphere language score on IAP, including expressive language, of the 5 cases reviewed. For all bilateral patients, MSI activation of classical temporal lobe language areas in the left hemisphere exceeded that seen on the right consistent with results of IAP. Of the 4 patients who were exclusively left dominant on IAP, 2 had activation of the right superior temporal gyrus.

CONCLUSION: Based on a limited number of cases, these data appear to confirm independent activation of specific right hemisphere language cortex in patients with IAP evidence of language function in both hemispheres. While right hemisphere MSI activation sites are present in patients who are exclusively left dominant on IAP, these activity sources may be less likely to correspond precisely with classical language areas.

Epilepsia 46(8);70[1.164]2005

Introduction:

Recent studies have reported a high rate of concordance between magnetoencephalography/magnetic source imaging (MSI) and the Intracarotid Amobarbital Procedure (IAP) in identifying patients with left hemisphere language dominance, despite the frequent co-occurrence of some right hemisphere activation on MSI^{1,2}. In a recent series studied at Minnesota Epilepsy Group, Doss reported an overall correct classification rate of 81% for identifying language in the hemisphere to be treated, although absolute concordance was lower due to poor agreement about patients classified as bilateral for language using either method³. This study examines the MSI anatomical activation patterns in the right hemisphere in response to an auditory word recognition task, in patients classified as having either bilateral language or exclusive left language dominance on IAP.

Methods:

Ten patients diagnosed with chronic epilepsy and/or brain tumor who had undergone the IAP and language mapping with MSI were retrospectively reviewed. Demographic data is presented in Table 1.

IAP language classification was based on correct language responses following each unilateral injection of amobarbital. Patients with correct responses scored following right injection, combined with global language impairment following left injection were considered to be left hemisphere dominant, while patients who demonstrated correct language responses following both injections (during maximum drug effect) were classified with bilateral language. It is important to note that, using these criteria, bilateral language does not mean bilaterally equivalent language functions.

MSI data were obtained with a 148-channel Magnes 2500 WH system (4-D Neuroimaging, San Diego, CA) and analyzed using the single equivalent dipole model. The MSI language activation task consisted of an auditory word recognition task (Apple Macintosh, Superlab software and sound amplification) that has been described previously and found to produce reliable activation in the temporal lobe and temporal parietal junction^{1,2}.

For each patient with bilateral language per IAP, the anatomic location of MSI language activation sites in the right hemisphere was examined in relation to correct modality-specific language responses of the right hemisphere following left injection on IAP. A similar examination of right hemisphere activation sites was conducted for those patients who showed no right hemisphere language ability on IAP.

Results

There were no significant differences between the language dominance groups on any demographic variable. Five of 6 patients who were classified as bilateral for language on IAP demonstrated some receptive language function in the right hemisphere and 4 of 6 had one or more correct responses on tasks of automatic speech and/or naming during maximum drug effect following the left injection. Right hemisphere IAP language responses for each patient in the bilateral group are listed in Table 2. This right hemisphere language appeared to represent a duplication of language functions also present in the left hemisphere. In all cases, the left hemisphere was superior in language performance compared to the right. There was no evidence of right hemisphere language in the left dominant group.

Table 3 shows the anatomic location of MSI language activation sites in the right hemisphere for bilateral compared to left dominant cases. Five of the 6 bilateral patients demonstrated activity sources in the right superior temporal gyrus (STG) or the temporal parietal junction (TPJ) (Fig. 1a). The remaining patient did not show any activation in the posterior language regions, but did demonstrate inferior frontal activation (Fig. 1b). Review of IAP language scores for this individual confirms expressive speech in the right hemisphere (Table 2). Of the IAP left dominant cases, two of four showed some activity sources in the right STG and TPJ (Fig. 1c). Of the remaining two cases, one showed no right hemisphere activation, while the other showed some activity in the inferior temporal gyrus only.

Conclusions:

- MSI activity sources in the right hemisphere of bilateral language patients clearly involve cortex homologous to primary left hemisphere language areas.
- Based on a limited sample, the right hemisphere activation sites for exclusively left dominant patients (per IAP) appear less consistent and/or less focal than those seen in bilateral cases.
- Continued comparison of nondominant hemisphere areas activated by this and other MSI language paradigms is necessary to improve the reliability of this method for language localization in clinical decision making.

References:

1. Breier JI, Simos PG, Zouridakis G, et al. Language dominance determined by magnetic source imaging; A comparison with the Wada procedure. *Neurology* 1999;53:938-945.
2. Papnicolaou, A.C., et al (2004). Magnetoencephalography: a noninvasive alternative to the Wada Procedure. *Journal of Neurosurgery*, 100, 867-876.
3. Doss R, Zhang W, Risse G, Gates J. Language Lateralization: A comparison of magnetic source imaging to the Wada procedure. Paper presented: M.E.G. Applications Conference, Xylocastro, Greece, September 2005.

Table 1

Demographic Information

IAP Language Classification	N	Sex	Handedness R/L		Age	Age at Seizure Onset	FSIQ
Bilateral	6	3 M, 3 F	6/0	Mean	21.3	15.5	100.8
				s.d.	6.0	9.6	11.3
Left	4	2 M, 2 F	3/1	Mean	23.3	15.5	89.3
				s.d.	6.8	8.2	15.2

M=male, F=female, s.d.=standard deviation

Table 2

IAP Right Hemisphere Language Responses

	Comprehension	Repetition	Reading	Auto Speech	Naming
IAP Bilateral Cases					
C.D.	X				
B.M.		X	X		
J.R.	X	X			
C.M.			X		
B.L.	X	X	X	X	X
J.H.					X

Table 3

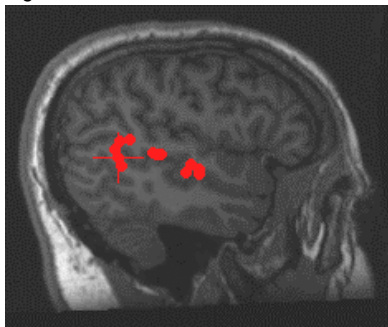
MSI Right Hemisphere Language Activation

	STG	MTG	TPJ	ITG	IF
IAP Bilateral Cases					
C.D.	X				X
B.M.*	X	X			
J.R.	X				
J.H.	X		X		
C.M.			X		
B.L.**					X
IAP Left Dominant Cases					
D.C.					
S.C.				X	
C.L.***	X		X		
M.O.	X		X		
STG=superior temporal gyrus, MTG=mesial temporal gyrus, TPJ=temporal parietal junction, ITG=inferior temporal gyrus, IF=inferior frontal region				* Figure 1a ** Figure 1b *** Figure 1c	

Figure 1

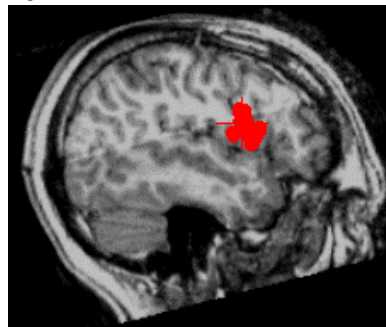
Right Hemisphere Language Activation

Figure 1a



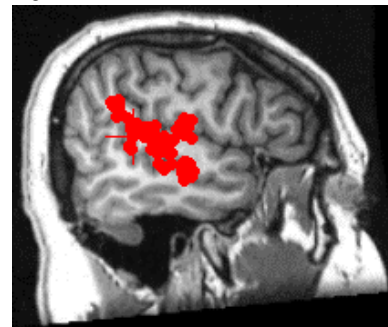
Bilateral patient (B.M.) showing right superior temporal activation

Figure 1b



Bilateral patient (B.L.) showing right inferior frontal activation

Figure 1c



Left dominant patient (C.L.) showing right superior temporal gyrus and temporal parietal junction activation.